CASE REPORT

AJO-DO

Treatment of Class II malocclusion with a customized lingual appliance combined with a Class II corrector

Alexandre Moro,[a] Nathaly Dias Morais,[b] Mike R. Bueno,[c] Karen Cristiane Almeida Stresser,[b] Tatiana Miranda Deliberador,[b] and Guilherme Janson[d]

Curitiba, Paraná; Cuiabá, Mato Grosso; and Bauru, São Paulo, Brazil

Correcting a complete Class II malocclusion in an adult patient can be quite difficult. If the patient has a large skeletal discrepancy, orthognathic surgery is the treatment of choice. However, if the discrepancy is small or if the situation is borderline and the mandibular incisors are retroclined, Class II correctors can be used. This clinical report presents the orthodontic treatment of a 24-year-old woman with Class II malocclusion. Clinically, her maxilla was slightly protruded, and the mandible was well-positioned. She had uprighted maxillary and mandibular anterior teeth and a deepbite, and she opted for a more esthetically appealing orthodontic appliance. The treatment plan included leveling and alignment of the teeth in both arches, Class II correction, establishing Class I molar and canine relationships, correction of overbite and overjet, adjustment of midlines, and improvement of facial and dental esthetics. Orthodontic treatment consisted of customized lingual appliances combined with a Class II fixed corrector. (Am J Orthod Dentofacial Orthop 2021;■:■-■)

The number of adult patients who have sought orthodontic care has increased in recent years. More often than not, these patients do not want to wear conventional metal appliances; however, there are only 3 alternatives for orthodontic treatment that are more esthetically pleasing, namely, ceramic brackets, removable aligners, and lingual appliances. For some patients, ceramic brackets do not meet their esthetic needs, as they stand out on smiling. Acceptability of removable aligners has increased among patients and orthodontists, but there is a paucity of studies corroborating their efficiency in Class II malocclusion treatment. As for lingual appliances, they are certainly the most esthetic, and some studies have shown good outcomes when these appliances are combined with Class II fixed appliances[1-3]; however, the technique cannot be easily mastered by many orthodontists.

Lingual orthodontic treatment is considered a bit more complex than conventional orthodontic treatment, as there are anatomic variations that hinder the assembly of the appliance.[4,5] In addition, the assembly results in some biomechanical issues for tooth movement. There is a reduction in interbracket distance, which interferes with torque control and, as a consequence, any change in bracket height can negatively influence torque.[4,5]

Currently, to overcome the difficulties with lingual orthodontic treatment, appliances have been manufactured by computer-aided methods.[4,6] The orthodontist scans or takes a silicon impression of the patient's teeth and sends a digital model or the silicon impression to the manufacturer, respectively. On the basis of information on the treatment provided by the orthodontist, a digital setup is sent to the orthodontist, who may suggest corrections or approve it. After approval, the brackets placed on an indirect bonding tray and the robotically bent archwires used during treatment are sent to the orthodontist. This approach greatly facilitated the use of lingual appliances and contributed to obtaining more predictable results.[7,8]

This clinical case report describes the orthodontic treatment of an adult patient with Class II malocclusion, uprighted mandibular and maxillary anterior teeth, and

[a]Graduate Program in Dentistry, School of Health Sciences, Universidade Positivo, and Department of Orthodontics, Federal University of Paraná, Curitiba, Paraná, Brazil.
[b]Graduate Program in Dentistry, School of Health Sciences, Universidade Positivo, Curitiba, Paraná, Brazil.
[c]Radiological Center of Orofacial Images, Cuiabá, Mato Grosso, Brazil.
[d]Department of Orthodontics, Bauru Dental School, University of São Paulo, Bauru, São Paulo, Brazil.
All authors have completed and submitted the ICMJE Form for Disclosure of Potential Conflicts of Interest, and none were reported.
Address correspondence to: Alexandre Moro, Rua Cel Dulcídeo, 1558, Água Verde 80250-100, Curitiba, Paraná, Brazil; e-mail, alexandremoro@uol.com.br.
Submitted, June 2020; revised and accepted, November 2020.
0889-5406/$36.00

https://doi.org/10.1016/j.ajodo.2020.11.041

Fig 1. Pretreatment facial and intraoral photographs.

marked overjet, who wanted to wear esthetic orthodontic appliances. A simple way to use a Class II corrector with lingual appliances will be demonstrated.

DIAGNOSIS AND ETIOLOGY

A 24-year-old woman sought dental care at our private practice to improve previous treatment. She had been wearing lingual appliances for nearly 3 years without satisfactory outcomes. Her teeth had been aligned, and space closure had been performed, but the Class II occlusal relationship was not corrected.

Clinically, the patient had a brachyfacial and convex profile, balanced nose and lips, passive lip seal, and symmetrical face (Fig 1). The relationship of the maxillary incisors with the upper lip was normal, and on smiling, the upper lip covered only 1 mm of the cervical region of the maxillary incisors. The patient had a mild Class II skeletal deformity. The maxilla was slightly protruded, and the mandible was well-positioned. There were no signs and symptoms of temporomandibular joint dysfunction.

Intraorally, the patient had a bilateral, complete[9,10] Class II molar relationship, the maxillary midline was coincident with the facial midline, and the mandibular midline exhibited a 1-mm rightward shift (Figs 1 and 2). The overjet measured 7.7 mm, and the overbite measured 4.8 mm. The curve of Spee was severe, with occlusal contacts only in the posterior teeth.

The panoramic radiograph showed that the maxillary third molars had been extracted and the mandibular third molars could become impacted (Fig 3). Cephalometrically, she had a Class I skeletal pattern (ANB, 1.9°) with a hypodivergent pattern (SN-GoGn, 23.5°). The maxillary (U1-NA, 5.8°) and mandibular incisors (IMPA, 80.8°) were uprighted. The nasolabial angle was within the normal range (NLA, 114.4°) (Fig 3; Table).

TREATMENT GOALS

The following treatment goals were established: (1) level and align the teeth in both dental arches; (2) correct the Class II relationship, finishing with molars and

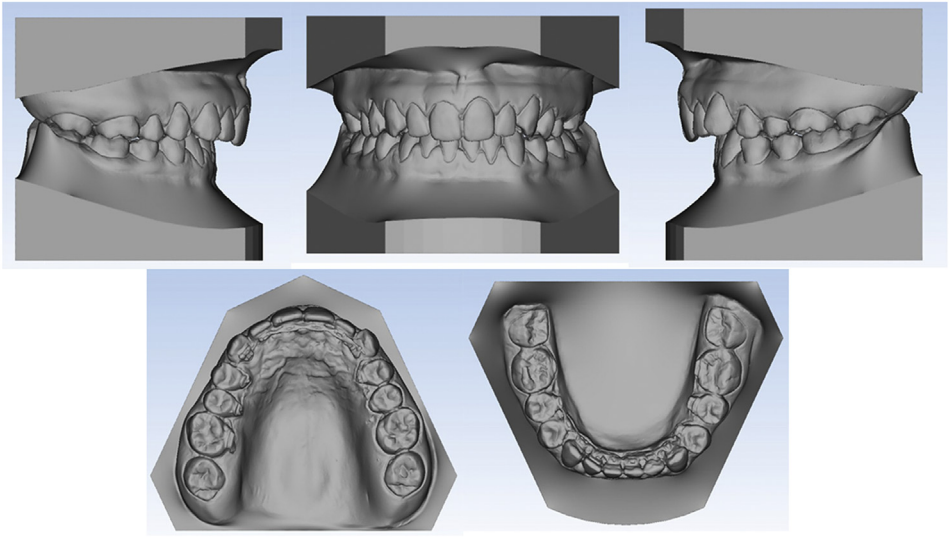

Fig 2. Pretreatment dental models.

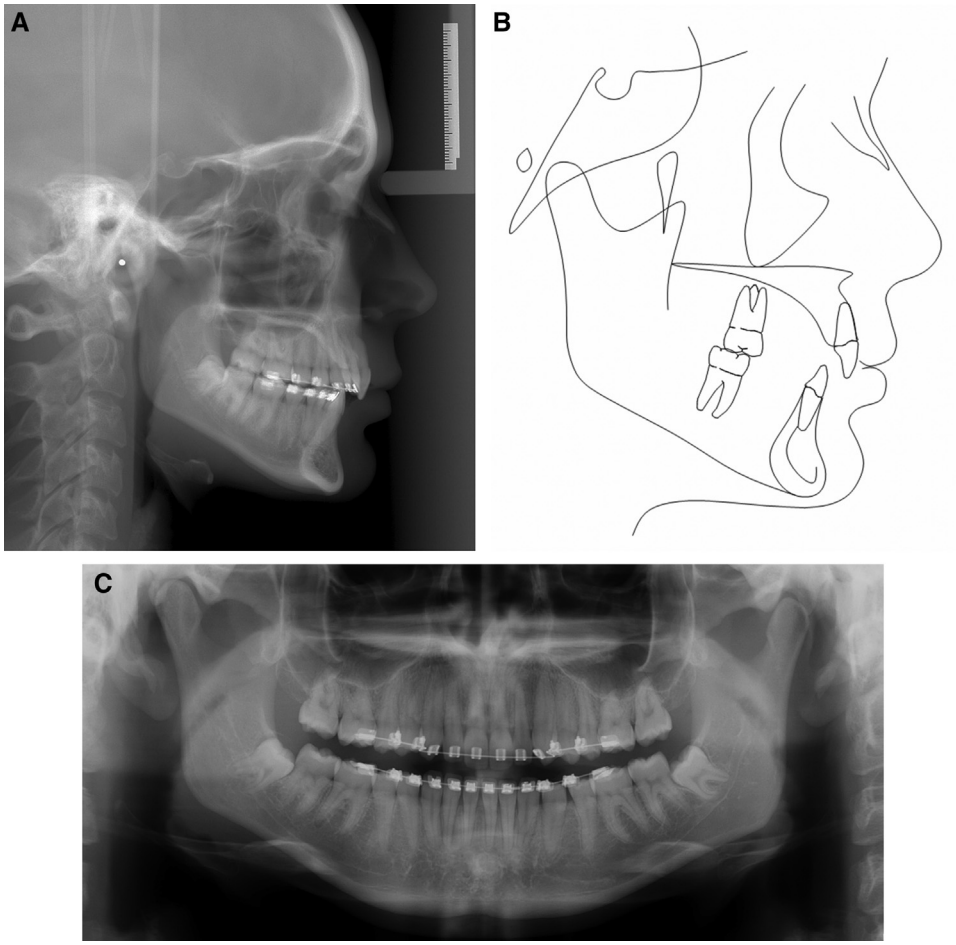

Fig 3. Pretreatment records: **A,** lateral cephalometric radiograph; **B,** cephalometric tracing; and **C,** panoramic radiograph.

Table. Cephalometric analysis

Variable	Norm	Pretreatment	Posttreatment	Two-year follow-up
Skeletal				
SNA, °	82.0	88.0	87.6	87.9
SNB, °	80.0	86.1	86.0	86.2
ANB, °	2.0	1.9	1.6	1.7
Wits appraisal, mm	0.0	−2.2	−5.3	−4.7
FMA (MP-FH), °	25.0	20.0	20.6	19.8
SN-GoGn, °	33.0	23.5	24	22.9
Y-axis, °	76.0	61.2	61.4	61.3
LAFH (ANS-Me), mm	76.0	62.2	62.7	62.4
SN-OP, °	14.0	9.4	14.0	13.5
Dental				
SN-U1, °	104.0	93.8	100.3	101.6
U1-NA, °	22.0	5.8	12.7	13.7
U1-NA, mm	4.0	4.1	2.6	2.9
L1-NB, °	25.0	13.4	19.4	20
L1-NB, mm	4.0	0.3	2.4	2.9
IMPA (L1-MP), °	90.0	80.8	86.9	87.2
Interincisal angle, °	131.0	158.9	146.3	144.6
Profile				
Upper lip to E-line, mm	−4.0	−2.7	−4.6	−4.0
Lower lip to E-line, mm	−2.0	−1.3	−2.5	−1.6
Nasolabial angle, °	110.0	114.4	113.9	112.0

canines in Class I relationship; (3) obtain normal overbite and overjet; (4) correct the mandibular midline discrepancy; and (5) improve dental and facial esthetics.

TREATMENT ALTERNATIVES

The first alternative would be to distalize the maxillary teeth with an intraoral distalizer, such as the pendulum appliance or mini-implants. Ideally, the pendulum appliance should be supported by skeletal anchorage.

Another option would be to level and align the teeth and extract 2 maxillary first premolars. Anchorage reinforcement would be needed because of the complete Class II anteroposterior relationship.

The third alternative used a fixed functional orthopedic appliance to correct her Class II occlusal relationship, associated with lingual appliances to correct the individual tooth positions and perform the finishing orthodontic procedures.

Because the patient did not want to use any skeletal anchorage and did not want to extract any tooth, she opted for the third alternative.

TREATMENT PROGRESS

The patient showed great concern about dental esthetics, and she wanted to keep on wearing lingual appliances instead of being treated with labial appliances. Therefore, the fully customized Harmony[11] (ASO International, Inc, Tokyo, Japan) appliance was chosen, which allows good control over tooth movement.

After patient consent, the current lingual appliance was removed, and silicone impressions were taken to manufacture the Harmony appliance. The impressions were sent with the appliance prescription form, along with the patient's photographs and radiographs, to start appliance manufacturing. As described in the form, the treatment would not include tooth extractions, and the Class II anteroposterior relationship would be corrected with the PowerScope[12-14] (American Orthodontics, Sheboygan, Wis) fixed functional appliance. An additional 10° labial crown torque was required for the maxillary incisors, which were initially uprighted. The digital setup, showing the treatment outcome, was then obtained, and the manufacturer began to fabricate the appliances (Fig 4).

Then, the maxillary and mandibular trays for indirect bonding of the appliances, the sequence of archwires for the maxillary and mandibular arches, and the jigs to bond the brackets on the anterior maxillary and mandibular teeth, should there be some debonding, were sent by the manufacturer. After indirect bonding of the appliances, treatment began with 0.014-in nickel-titanium archwires in both dental arches. Maxillary molars buildups (Triad gel; Dentsply Sirona, Charlotte, NC) were used to open the bite and avoid possible impingement of the mandibular incisors on the maxillary incisor brackets (Fig 5). Subsequently, 0.016 × 0.016-in, 0.016 × 0.022-in, and 0.018 × 0.025-in nickel-titanium archwires were used (Fig 6). PowerScope was installed with this archwire. A 0.019 × 0.025-in stainless steel wire segment was bonded on the buccal surface of the mandibular premolars, whereas in the maxillary arch, a wire segment was bonded on the maxillary first and second molars to support the PowerScope (Fig 7).

PowerScope was totally activated when it was placed. The intermediate tube of the telescopic system remained completely inside the maxillary tube, except for its 1.5-mm inferior depression, promoting total compression of the spring, generating 260 g of force. During treatment, PowerScope was usually monthly activated with 1 mm spacers on the right and left telescopic systems. However, to manage different anteroposterior discrepancy correction and to correct mandibular to maxillary midline deviation, asymmetric activations were also used. Class II correction took 8 months, and PowerScope



Fig 4. Digital setup: **A,** initial occlusal relationship; **B,** simulation of final occlusal relationship; **C,** superimposition of initial (*gray*) and final (*blue*) occlusal relationships.

was removed after slight overcorrection of the anteroposterior relationship, as evaluated with the mandible in centric relation (Fig 8). To maintain the correction and prevent relapse, the patient wore Class II elastics during sleep for 6 months. Interdigitation was achieved after arch coordination. In the finishing stage, 0.016 × 0.022-in titanium molybdenum flexible archwires were used (Fig 9). Despite the customized appliance fabrication, including brackets and wires, for the perfect fit of the teeth, several individual bends were necessary for the archwires to conclude treatment. After 34 months, the appliances were removed, and fixed canine-to-canine bonded maxillary and mandibular retainers were placed (Fig 10). In addition, an Essix (Ace 0.040-in; Dentsply Raintree Essix, Sarasota, Fla) retainer was worn during sleep.

Fig 5. Harmony brackets bonded in maxillary and mandibular arches. Initial maxillary and mandibular 0.014-in nickel-titanium archwires were placed.

Fig 6. Maxillary 0.016 × 0.022-in and mandibular 0.018 × 0.025-in nickel-titanium archwires were placed 1 month before PowerScope insertion.

TREATMENT OUTCOMES

The posttreatment assessment shows that the treatment goals were attained (Figs 10 and 11). Facial esthetics improved, with better distribution of teeth along with smile. The Class II relationship was corrected along with the deepbite and overjet. A good occlusion was achieved. The posttreatment panoramic radiograph shows satisfactory root alignment and no evidence of significant root resorption (Fig 12). The patient was referred to an oral surgeon for extractions of her mandibular third molars; however, she refused to extract them.

Fig 7. Midtreatment insertion of PowerScope. Segmental 0.019 × 0.025-in stainless steel wire for PowerScope nuts on the maxillary and mandibular arches.

Fig 8. A-C, after removal of PowerScope appliance. **D,** Class II elastics used to maintain the correction.

The cephalometric variables show a slight reduction in the basal bone relationship (ANB) and labial tipping and retrusion of the maxillary incisors in relation to A point (Fig 12; Table). There was also labial tipping and protrusion of the mandibular incisors. Labial tipping of the mandibular incisors provided support for the lower lip, contributing to facial profile improvement. The esthetic and functional objectives were achieved.

The patient was very satisfied with the great facial improvement and short treatment time. The 2-year posttreatment photographs, dental models, and radiographs show excellent stability of the treatment results (Figs 13-15). Cephalometric superimpositions of the initial, final, and follow-up lateral cephalometric tracings illustrate the skeletal and dentoalveolar changes with treatment and in the posttreatment period (Fig 16). There was very slight retrusion of the maxilla and retrusion of the maxillary incisors.

DISCUSSION

It is quite difficult to fully correct a Class II malocclusion in an adult patient. In case of large skeletal discrepancy, orthognathic surgery is the treatment of choice.[15,16] However, if the discrepancy is small or it is a borderline diagnosis, other treatment options are available.[17,18] Because of limited skeletal effects and negligible changes in the profile, Class II correctors are indicated for patients with a moderate diagnosis with retroclined mandibular incisors, which perfectly matched the patient described.[19]

Fig 9. Maxillary and mandibular 0.016 × 0.022-in titanium molybdenum archwires with finishing bends.

Fig 10. Posttreatment facial and intraoral photographs.

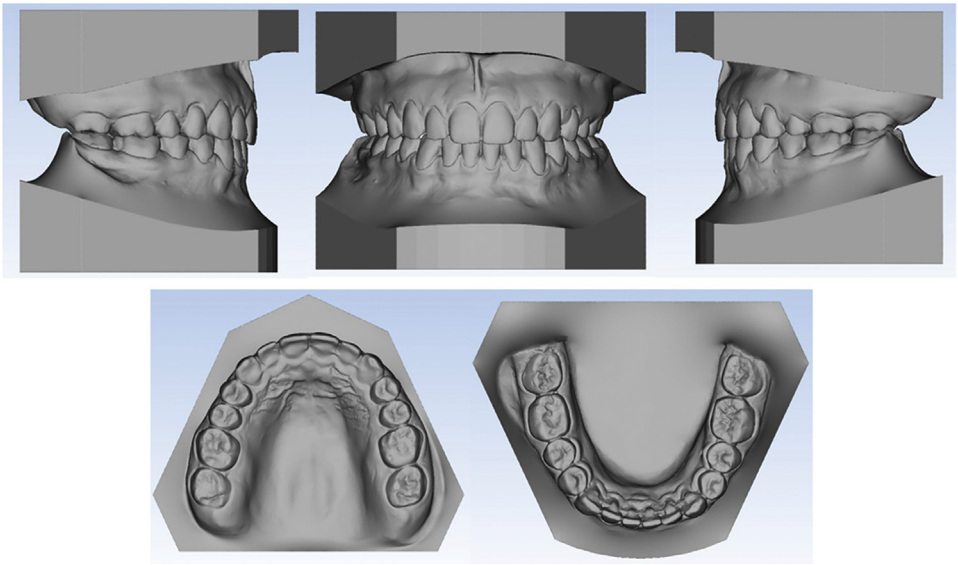

Fig 11. Posttreatment dental models.

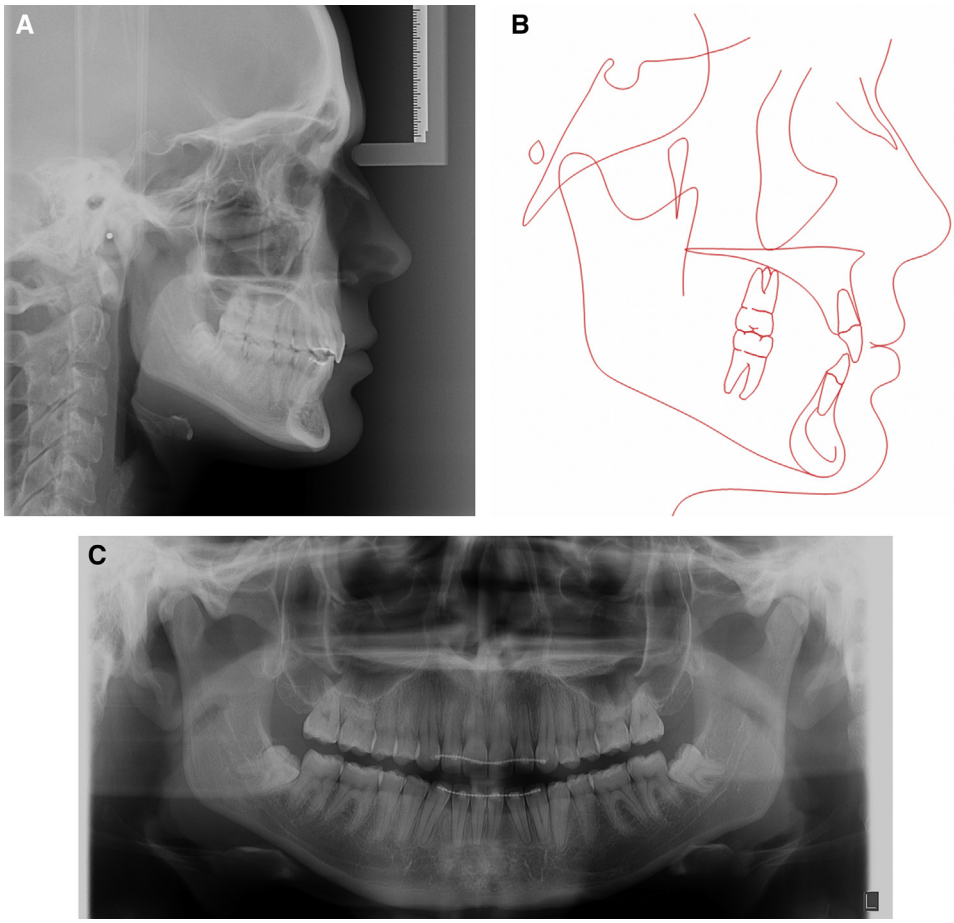

Fig 12. Posttreatment records: **A,** lateral cephalometric radiograph; **B,** cephalometric tracing; **C,** panoramic radiograph.

Fig 13. Two-years posttreatment follow-up showing excellent stability.

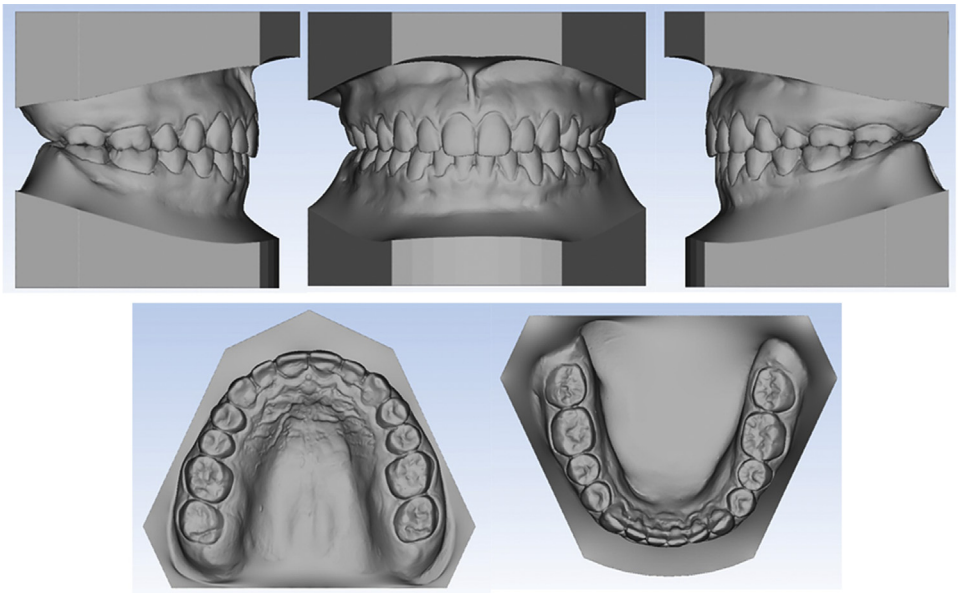

Fig 14. Posttreatment follow-up dental models.

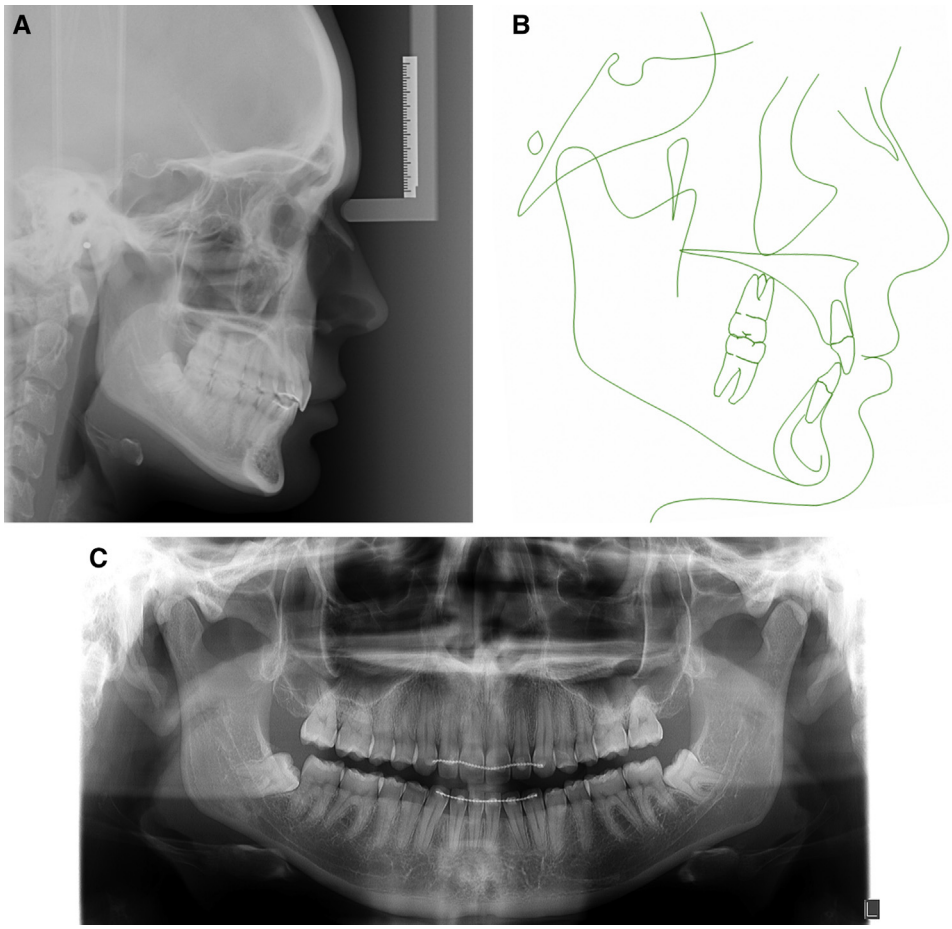

Fig 15. Posttreatment follow-up records: **A,** lateral cephalometric radiograph; **B,** cephalometric tracing; **C,** panoramic radiograph.

The fact that the patient opted for a lingual appliance was a hindrance to treatment. In the lingual approach, first and third-order tooth movements are complicated by the lingual dental anatomy variability, and the short interbracket distances interfere with torque control.[4,5] To overcome these problems, digital lingual appliances were manufactured. These appliances are costly, the learning curve for mastering the technique is steep, and much training is required. However, if properly carried out, the technique provides good outcomes, often similar to conventional metal appliances installed on the vestibular surface.[20] Fabrication of computer-aided appliances has provided greater accuracy as these appliances are customized for each patient, facilitating clinical use.[21]

The Harmony appliance is ideal for more complex esthetic diagnoses, as the one described herein. It was developed after the lingual Incognito appliance system and had some improvements as Interactive self-ligating brackets and anterior repositioning jigs.[11,22] One of its main advantages is the digital setup obtained by computer-aided design–computer-aided manufacturing, allowing the orthodontist to establish his goals and mechanics before treatment. This technology was assessed in another study,[7] and according to the authors, these fully customized lingual orthodontic appliances were accurate in achieving the goals planned at the initial setup, except for the full amount of planned expansion and inclination of the second molars.

However, even though the appliance was totally designed by a computer program, bends still had to be performed on 0.016 × 0.022-in titanium molybdenum archwires to improve interdigitation. Despite the technology used in this case, the appliance per se could not provide excellent outcomes. Details of the occlusion at the end were quite laborious and prolonged the treatment time to 34 months.

Although additional labial crown torque of 10° for the maxillary incisors was requested, the superimposed cephalometric tracings show that the maxillary incisors

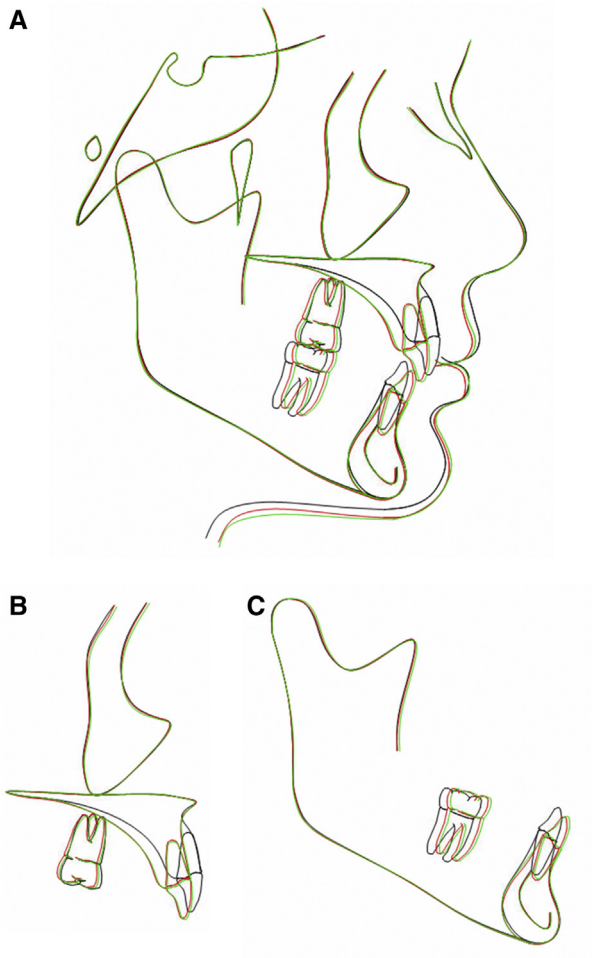

Fig 16. Cephalometric superimpositions[39] of the initial (*black*), final (*red*), and follow-up (*green*) lateral cephalometric tracings: **A,** cranial base, centered at the anterior wall of sella turcica, cerebral surface of the orbital part of the frontal bone, and a cribriform plate of the ethmoid; **B,** maxilla, centered at the zygomatic process; **C,** mandibular plane, centered on the symphysis.

were still slightly uprighted (Fig 16). However, the smile esthetics was not affected, as can be seen in the final photographs (Fig 10).

As far as Class II malocclusion is concerned, different methods exist which use conventional appliances to correct it, but when nonvisible appliances are used, the options are limited, especially regarding removable aligners.[22] This technique has been based mainly on the use of Class II elastics. For Invisalign (Align Technology, Santa Clara, Calif), the technique follows some protocols for distalization of the maxillary teeth and mesialization of the mandibular teeth, but no rigorous scientific evaluation has been conducted. Clinically, these new methods may fail to correct Class II malocclusions with a 6-mm molar relationship discrepancy. Invisalign requires the use of several aligners, and there are some clinical patients that require more than 100 aligners.[23] In addition, the orthodontist has to rely on patient compliance with the use of Class II elastics.

PowerScope is a hybrid, fixed, and one-size-fits-all appliance. It has a spring within the telescopic system, which is a trend in current mandibular protraction appliances. This prevents the accumulation of food residues during chewing and injury to the cheeks. Moreover, its placement is quicker and easier when compared with the Herbst appliance, which requires a laboratory phase for its manufacture.[24] This appliance has a telescoping mechanism that can be continuously activated during treatment through "shims." The nickel-titanium spring, when fully activated (~5 mm), generates 260 g of force.[14] As the teeth move, the spring deactivates. Because molar correction occurs at around 1 mm per month, loss of force is large, and thus the appliance has to be reactivated in each visit using a 1-mm spacer.[14] PowerScope is indicated for use as Class II mechanics, either bilateral or unilateral, and in compensatory Class II treatment.[14]

In the described patient, PowerScope was efficient both esthetically and functionally, as the Class II discrepancy correction was complete. Other therapeutic approaches, such as extractions of the first 2 maxillary premolars and distalization of the maxillary teeth with an intraoral distalizer (eg, pendulum appliance or mini-implants), were not accepted by the patient. In addition, she did not want to have temporary spaces between her teeth during treatment. Given the clinically small maxillary protrusion, the acceptable facial profile, and the patient's main complaint was the poor esthetics of the anterior teeth, Class II correction with orthognathic surgery was also refuted. PowerScope was used because of retroclination of the mandibular anterior teeth. This device corrects Class II malocclusion with tooth movement, including protrusion of the mandibular teeth.[25] A virtual setup was used to manufacture the Harmony appliance, which changed Class II into Class I, predicting the correction performed with PowerScope. This simulation allowed assessing what the occlusion would look like at the end of treatment, and superimposition of the baseline and final dental models determined to what extent the occlusion should be modified to achieve the desired outcome (Fig 4). The use of PowerScope was under consideration for the successful correction of a complete Class II malocclusion. The superimpositions demonstrate that correction was obtained mainly through mesialization of the mandibular teeth (Fig 16). This is in accordance with the

literature as an effect of PowerScope.[25] In addition, slight distalization of the maxillary molars also contributed to molar relationship correction.

An important aspect of Class II correction with either lingual or vestibular appliances with Class II correctors is overcorrection. In this approach, it is preferred to overcorrect the posterior segment in 2 mm (Fig 8). After removing PowerScope, Class II elastics were worn by the patient during sleep, and the final occlusal finishing was controlled with them.

Mandibular protraction appliances are not designed to fit into lingual appliances, but the literature describes clinical patients in which a method was developed to solve this problem or some adaptation was used.[26-29] There have been reports of patients treated with a hybrid system (ie, with a lingual appliance in the maxillary arch and a conventional vestibular appliance in the mandibular arch). In addition, there have been reports of the use of a mandibular protraction appliance in a system with both arches treated with lingual appliances. Although the wire segment used in our clinical case showed good strength to support the mandibular protraction appliance, the maxillary sectional wire became loose once, on the right side, during the 8 months of treatment with PowerScope.

The current case report demonstrates that the use of proper technology and the right tools may bring good outcomes even in patients with more complex diagnoses, such as the one addressed herein. Thus, complex Class II malocclusions can be treated without neglecting to obtain details of the occlusal relationships as observed in patients treated with aligners.[30]

Currently, besides esthetics, patients are also concerned with factors such as comfort and pain. Although conventional orthodontic appliances are the most frequently used devices, studies show that nonvisible appliances have increasingly stood out, which is the case with lingual appliances and aligners.[31-34] With regard to tongue and speech disturbances, the patient adapted perfectly to the lingual appliances, and because of that, she decided to keep wearing it in the second treatment. Some studies have already compared lingual and conventional appliances regarding pain and changes in speech, revealing no significant differences between them.[35] Patients who wore lingual appliances described greater difficulty in speaking and discomfort with their tongues, especially in the first 3 weeks.[32,36,37]

Another concern with lingual appliances is the patient's periodontal health. Some studies comparing Invisalign and lingual appliances showed that periodontal indexes were significantly better with aligners than lingual appliances, but the probed sulcus depth was similar.[38] In the case reported, the patient had mild inflammation in her gingiva with the use of lingual appliances, but that did not interfere with treatment.

The combination of a PowerScope device with Harmony appliances is esthetic, predictable, and efficient treatment option for some patients with Class II malocclusions, especially if compliance and esthetics are an issue.

CONCLUSIONS

The incorporation of a Class II corrector with customized lingual appliances has enabled orthodontists to provide efficient, invisible, compliance-free correction of moderate to severe Class II malocclusions.

AUTHOR CREDIT STATEMENT

Alexandre Moro contributed to treatment, analysis, and interpretation of data, original draft preparation, and manuscript review and editing; Nathaly Dias Morais contributed to analysis and interpretation of data and original draft preparation. Mike R. Bueno contributed to the collection, analysis, and interpretation of data; Karen Cristiane Almeida Stresser, analysis and interpretation of data and original draft preparation; Tatiana Miranda Deliberador contributed to study conception and design and manuscript review and editing; and Guilherme Janson contributed to manuscript review and editing.

REFERENCES

1. Bock NC, Ruf S, Wiechmann D, Jilek T. Herbst plus lingual versus Herbst plus labial: a comparison of occlusal outcome and gingival health. Eur J Orthod 2016;38:478-84.
2. Wiechmann D, Schwestka-Polly R, Pancherz H, Hohoff A. Control of mandibular incisors with the combined Herbst and completely customized lingual appliance—a pilot study. Head Face Med 2010;6:3.
3. Wiechmann D, Vu J, Schwestka-Polly R, Helms HJ, Knösel M. Clinical complications during treatment with a modified Herbst appliance in combination with a lingual appliance. Head Face Med 2015;11:31.
4. Rummel V, Wiechmann D, Sachdeva RCL. Precision finishing in lingual orthodontics. J Clin Orthod 1999;33:101-13.
5. Macchi A, Tagliabue A, Levrini L, Trezzi G. Philippe self-ligating lingual brackets. J Clin Orthod 2002;36:42-5.
6. Fillion D. The lingual liberty system: advantages of a digital lingual straight wire system. Semin Orthod 2018;24:286-96.
7. Grauer D, Proffit WR. Accuracy in tooth positioning with a fully customized lingual orthodontic appliance. Am J Orthod Dentofacial Orthop 2011;140:433-43.
8. Mistakidis I, Katib H, Vasilakos G, Kloukos D, Gkantidis N. Clinical outcomes of lingual orthodontic treatment: a systematic review. Eur J Orthod 2016;38:447-58.
9. Andrews LF. The straight-wire appliance: Syllabus of philosophy and techniques. 2nd ed. San Diego: Larry F. Andrews Foundation of Orthodontic Education and Research; 1975. p. 109-41.

10. Wheeler TT, McGorray SP, Dolce C, Taylor MG, King GJ. Effectiveness of early treatment of Class II malocclusion. Am J Orthod Dentofacial Orthop 2002;121:9-17.
11. Curiel PC. Harmony—the invisible solution for a perfect smile. Orthotown 2012;26-9.
12. Hayes A. Premolar substitution utilizing the PowerScope Class II corrector after extracting transmigrated mandibular canines. Orthotown 2014;1:24-32.
13. Moro A. Simplified correction of Class II using PowerScope. Orthotown 2016;9:20-7.
14. Moro A, Borges SW, Spada PP, Morais ND, Correr GM, Chaves CM Jr, et al. Twenty-year clinical experience with fixed functional appliances. Dental Press J Orthod 2018;23:87-109.
15. Mihalik CA, Proffit WR, Phillips C. Long-term follow-up of Class II adults treated with orthodontic camouflage: a comparison with orthognathic surgery outcomes. Am J Orthod Dentofacial Orthop 2003;123:266-78.
16. Raposo R, Peleteiro B, Paço M, Pinho T. Orthodontic camouflage versus orthodontic-orthognathic surgical treatment in Class II malocclusion: a systematic review and meta-analysis. Int J Oral Maxillofac Surg 2018;47:445-55.
17. Cassidy DW Jr, Herbosa EG, Rotskoff KS, Johnston LE Jr. A comparison of surgery and orthodontics in "borderline" adults with Class II, Division 1 malocclusions. Am J Orthod Dentofacial Orthop 1993;104:455-70.
18. Upadhyay M, Yadav S, Nagaraj K, Uribe F, Nanda R. Mini-implants vs fixed functional appliances for treatment of young adult Class II female patients: a prospective clinical trial. Angle Orthod 2012;82:294-303.
19. Kinzinger G, Frye L, Diedrich P. Class II treatment in adults: comparing camouflage orthodontics, dentofacial orthopedics and orthognathic surgery–a cephalometric study to evaluate various therapeutic effects. J Orofac Orthop 2009;70:63-91.
20. Ata-Ali F, Plasencia E, Lanuza-Garcia A, Ferrer-Molina M, Melo M, Ata-Ali J. Effectiveness of lingual versus labial fixed appliances in adults according to the peer assessment rating index. Am J Orthod Dentofacial Orthop 2019;155:819-25.
21. Riolo C, Finkleman SA, Kaltschmidt C. Lingual orthodontics: understanding the issues is the key to success with lingual mechanics. Semin Orthod 2018;24:271-85.
22. Moro A, Bubadra PG, Barros T Jr, Schimim SC, Morais ND, Correr GM. [Lingual orthodontics x removable aligners: when to use]. Ortho Sci Pract 2017;10:104-30: Portuguese.
23. Ojima K, Dan C, Watanabe H, Kumagai Y. Upper molar distalization with Invisalign treatment accelerated by Photobiomodulation. J Clin Orthod 2018;52:675-83.
24. Moro A, Mattos CFP, Morais ND, Borges SW, Nolasco GMC, Topolski F. [Five year clinical evaluation of the PowerScope Class II corrector]. Orthod Sci Pract 2019;12:25-40: Portuguese.
25. Arora V, Sharma R, Chowdhary S. Comparative evaluation of treatment effects between two fixed functional appliances for correction of Class II malocclusion: a single-center, randomized controlled trial. Angle Orthod 2018;88:259-66.
26. Wiechmann D, Schwestka-Polly R, Hohoff A. Herbst appliance in lingual orthodontics. Am J Orthod Dentofacial Orthop 2008;134:439-46.
27. Kravitz ND. Incorporating the Forsus Fatigue Resistant Device with the Incognito Appliance System. Orthod Perspectives 2012;17:3-5.
28. Vu J, Pancherz H, Schwestka-Polly R, Wiechmann D. Correction of Class II, Division 2 malocclusions using a completely customized lingual appliance and the Herbst device. J Orofac Orthop 2012;73:225-35.
29. O'Keeffe C, O'Keeffe ME. Class II therapy with a combination of customized lingual appliances and the Forsus device. J Clin Orthod 2013;47:464-70.
30. Nicolay O, Cisneros GJ. Treatment of adult patients with esthetic appliances: does appliance selection dictate the treatment plan? Semin Orthod 2018;24:351-7.
31. Hohoff A, Wiechmann D, Fillion D, Stamm T, Lippold C, Ehmer U. Evaluation of the parameters underlying the decision by adult patients to opt for lingual therapy: an international comparison. J Orofac Orthop 2003;64:135-44.
32. Fritz U, Diedrich P, Wiechmann D. Lingual technique—patients' characteristics, motivation and acceptance. Interpretation of a retrospective survey. J Orofac Orthop 2002;63:227-33.
33. Nedwed V, Miethke RR. Motivation, acceptance and problems of Invisalign patients. J Orofac Orthop 2005;66:162-73.
34. Meier B, Wiemer KB, Miethke RR. Invisalign—patient profiling. Analysis of a prospective survey. J Orofac Orthop 2003;64:352-8.
35. Wu AK, McGrath C, Wong RW, Wiechmann D, Rabie AB. A comparison of pain experienced by patients treated with labial and lingual orthodontic appliances. Eur J Orthod 2010;32:403-7.
36. Caniklioglu C, Oztürk Y. Patient discomfort: a comparison between lingual and labial fixed appliances. Angle Orthod 2005;75:86-91.
37. Papageorgiou SN, Gölz L, Jäger A, Eliades T, Bourauel C. Lingual vs. labial fixed orthodontic appliances: systematic review and meta-analysis of treatment effects. Eur J Oral Sci 2016;124:105-18.
38. Miethke RR, Brauner K. A comparison of the periodontal health of patients during treatment with the Invisalign system and with fixed lingual appliances. J Orofac Orthop 2007;68:223-31.
39. American Board of Orthodontics. Superimpositions. Available at: https://ntiiiby.americanboardortho.com/orthodontists/become-certified/clinical-exam/scenario-based-clinical-examination/scenario-based-exam-preparation/. Accessed November 2, 2021.