

---

# Molar Distalization With the Herbst Appliance

Mesou Lai

**This article reviews the dental effects of the Herbst appliance as well as its long-term effects on the dentition. The Herbst appliance exhibits a pronounced high-pull headgear effect on the maxillary molars. Without retention, the molars tend to return to their former anteroposterior positions after the removal of the appliance. These distal movements of the maxillary molars are favorable in Class II correction. Reciprocal mesial movements of the mandibular dentition, however, may not be desirable in many instances. Even though partial recovery occurs after Herbst therapy, treatment effects can persist in the mandibular arch. The latter effect can be beneficial to those patients who have initial retroclined mandibular incisors, but unfavorable in those patients with proclined lower incisors at the beginning of treatment. (Semin Orthod 2000;6:119-128.) Copyright © 2000 by W.B. Saunders Company**

One common problem facing orthodontists is the treatment of Class II malocclusions. In correcting this type of malocclusion into a Class I relationship, one or more of a variety of changes in anteroposterior relations must occur, including distal movement of maxillary teeth, mesial movement of mandibular teeth, growth, and/or orthopedic changes of apical basal skeletons. The Herbst appliance, developed by Emil Herbst<sup>1,2</sup> in 1905, has been used in an attempt to alter the amount and direction of basal bone growth.

The Herbst appliance is a bite-jumping device that features a bilateral telescoping mechanism. Telescopic tube-and-rod assemblies extend from the region of the maxillary first molars to the region of the mandibular premolars and keep the mandible in a constantly protruded position. The Herbst appliance is used mainly in the correction of Class II malocclusions. In addition, this appliance can be used as an anchorage appliance for space closure<sup>3,4</sup> during protraction

of the mandibular molars or during retraction of the maxillary buccal segment after molar distalization.<sup>5</sup>

Class II treatment with the Herbst appliance has gained increasing popularity since it was reintroduced by Pancherz in 1979.<sup>6</sup> Many articles on appliance design as well as clinical management of the appliance have been published since that time.<sup>7-21</sup> The banded design of Pancherz<sup>6</sup> has been modified in various ways in an attempt to improve treatment efficacy. For example, stainless steel crowns have been substituted for bands on the anchor teeth.<sup>7-11</sup> Cast splints<sup>12</sup> and acrylic splints<sup>13-17</sup> also have been used to carry the telescope mechanism. Flexible spring modules have been substituted for the rigid tube-and-rod design to allow greater range of mandibular movements.<sup>18</sup> A cantilever design is particularly beneficial during early Herbst therapy before the eruption of the mandibular first premolars.<sup>3,4,19</sup>

During the past 2 decades, many studies have been performed to evaluate the treatment effects of the Herbst appliances on the craniofacial skeleton.<sup>22-47</sup> Dentoalveolar as well as skeletal changes contribute greatly to the Class II correction during Herbst treatment. This article reviews the dentoalveolar effects of the Herbst appliance as well as its long-term effects on the dentition. Maxillary incisors are not always incor-

---

*From the Division of Orthodontics, Department of Growth and Development, Harvard School of Dental Medicine, Boston, MA.*

*Address correspondence to Mesou Lai, BDS, DDS, MS, Harvard School of Dental Medicine, Department of Growth and Development, 188 Longwood Ave, Boston, MA 02115.*

*Copyright © 2000 by W.B. Saunders Company*

*1073-8746/00/0602-0006\$10.00/0*

*doi:10.1053/od.2000.5898*

porated into the appliance; therefore, movement of the maxillary incisors is not considered in this article. This article does not intend to compare the effects among the different designs because other factors affecting treatment, such as gender, age at start of treatment, length of treatment, or treatment protocol, vary among these studies.

## Effects on the Maxillary Dentition

### Changes During Therapy

The Herbst appliance is completely tooth-borne and uses both the maxillary and mandibular dentition to transfer the force exerted from the telescopic arms of the Herbst bite-jumping mechanism to the bases of the maxilla and the mandible. The telescopic system produces a posterosuperiorly directed force on the maxillary posterior teeth and an anteriorly directed force on the mandibular dentition. As a result, Class II molar correction generally is a combination of skeletal and dentoalveolar changes irrespective of facial morphology<sup>22,23</sup> or ethnic background.<sup>24,25</sup> The skeletal changes are the result of differential growth between the mandible and the maxilla. Dentoalveolar movements include both the distal movement of the maxillary molars and mesial movement of the mandibular molars.

The skeletal and dentoalveolar contributions to Class II molar correction during Herbst

therapy derived from different studies are listed in Table 1.<sup>22,23,25-33</sup> In the majority of studies, distal tooth movements of maxillary molars, secondary to mandibular skeletal changes, contribute significantly to the sagittal molar correction, though there is a large variation in the amount of maxillary molar distalization among these studies. In general, maxillary molar distalization has been shown to comprise approximately 25% to 40% of molar correction with the banded Herbst appliance,<sup>22,23,25-29</sup> whereas in the acrylic design it accounts for 20% to 25% of the correction.<sup>31-33</sup> Superimposed cephalometric tracings showing the treatment changes of 40 Class II Division 1 patients treated with the acrylic-splint Herbst appliance from a previous study<sup>32</sup> are shown in Figure 1.

The distal movements of the upper molars, in contrast to the normal growth pattern in which these teeth migrate mesially through the alveolar processes, indicate that the Herbst appliance has a pronounced distalizing effect on the maxillary molars.<sup>26,31,33-35</sup> In addition, the eruption of the maxillary posterior teeth are inhibited by the appliance.<sup>30,32,35</sup> Displacements of the maxillary molars by the Herbst appliance as well as control data from previously published studies are shown in Table 2. Differences between the mean changes in the two groups are considered to be the treatment effects. The distalizing effects are reported to range from an average of 1.8 mm in the study by Franchi et al<sup>33</sup> to 2.8 mm in the study

**Table 1.** Skeletal and Dental Components of Class II Molar Correction During Herbst Therapy

Authors	Sample Size	Age (y)	Tx Interval (mo)	Molar Correction	Skeletal Changes		Dental Changes	
					Maxilla	Mandible	Maxilla	Mandible
Pancherz <sup>26</sup> 1982	22	12.1	6	+6.7	-0.3	+3.1	+2.6	+1.3
Pancherz et al <sup>27</sup> 1986	40	12.5	7	+6.3	-0.3	+2.5	+2.0	+2.1
Pancherz et al <sup>28</sup> 1989	18	10-13	6	+6.4	-0.1	+1.9	+2.7	+1.9
Ruf et al <sup>22</sup> 1997	16	11-14	7	+6.4*	-0.2	+3.0	+1.5	+2.1
	15	11-14	7	+5.7†	-0.5	+1.9	+2.4	+1.9
Objjou et al <sup>23</sup> 1997	14	Prepubertal/pubertal	7.5	+5.9‡	-0.8	+3.5	+1.6	+1.6
Wong et al <sup>25</sup> 1997	14	13.4	6-8	+7.2§	-0.2	+3.4	+1.9	+2.1
	14	13.3	6-8	+6.7	-0.3	+2.3	+2.6	+2.1
Konik et al <sup>29</sup> 1997	21	Postpubertal	7.7	+6.1	-0.1	+2.4	+2.0	+1.8
Valant et al <sup>30</sup> 1989	32	10.2	10	+7.1	+0.7	+3.3	+1.5	+1.6
Windmiller <sup>31</sup> 1993	46	13.1	11.6	+5.4	-1.0	+4.0	+1.0	+1.4
Lai et al <sup>32</sup> 1998	40	13.0	12	+5.7	-1.0	+4.1	+1.3	+1.3
Franchi et al <sup>33</sup> 1999	55	12.8	12	+5.3	-0.6	+3.1	+1.4	+1.4

NOTE. +, Indicates favorable change for correction; -, indicates unfavorable change for correction.

\*Hyperdivergent.

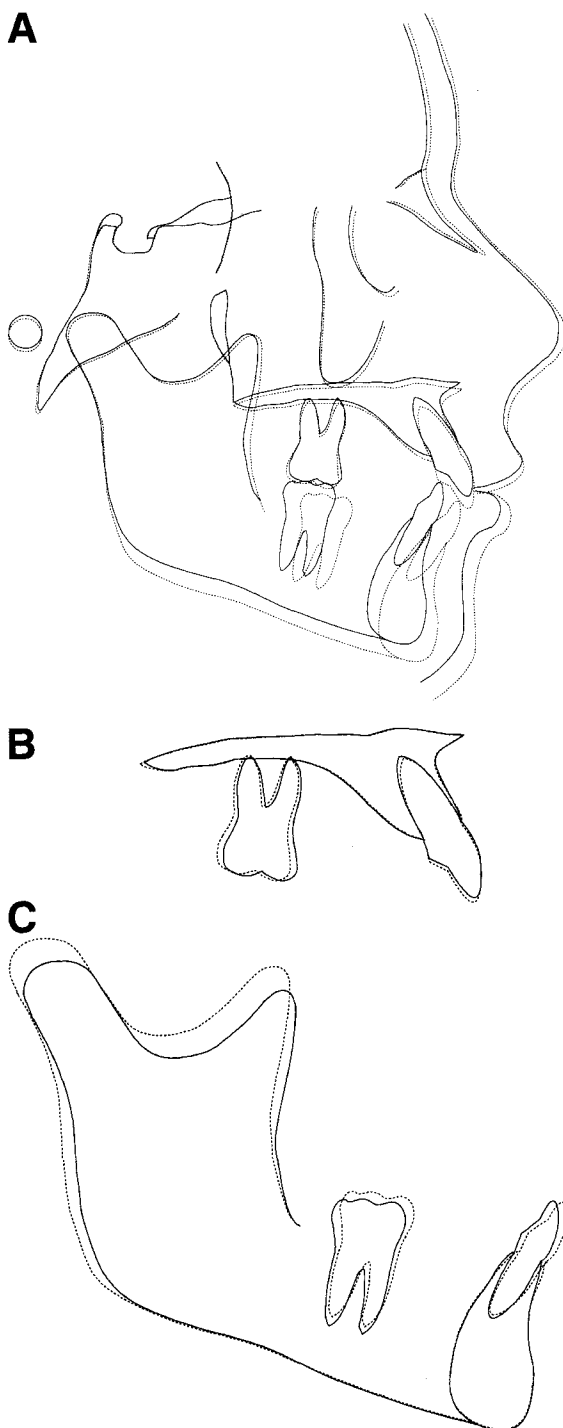
†Hypodivergent.

‡Class II Division 2.

§Chinese sample.

||Caucasian sample.

by Pancherz.<sup>26</sup> The intrusive effects are approximately 1 mm.<sup>30,32,35</sup> The amount of distal and vertical movements of maxillary molars is found to be independent of the presence or absence of erupted second molars<sup>35</sup> or of the somatic maturity level of patients at the start of treatment.<sup>29,35</sup>



### Posttreatment Changes

Generally, the Class II relationship is overcorrected into a Class III relationship with an unstable intercuspation at the end of Herbst treatment (Fig 1). Following the removal of the appliance, the occlusion then settles into a Class I relationship mainly as a result of dental relapse, which includes mesial movement of the maxillary molars and distal movement of the mandibular molars.<sup>26,27,32,33,35</sup> In the maxilla, the molars tend to return to their original position after the treatment is discontinued, resulting in little contribution to the Class II molar correction. The contribution of maxillary molar distalization decreases to 11% at the end of the 12-month posttreatment period (0.5 mm of 4.6 mm correction).<sup>26</sup> Two studies evaluating two-phase treatment with the acrylic Herbst appliance reported no contribution at all at the end of second phase treatment.<sup>32,33</sup> The skeletal and dentoalveolar changes that accomplish the Class II molar correction when the Class I sagittal relationship is established are presented in Table 3. Figure 2 shows the treatment changes of 40 patients treated with the acrylic Herbst immediately followed up by edgewise therapy.<sup>32</sup>

During a post-Herbst period of 16 months, Franchi et al<sup>33</sup> reported that the anterior movement of the maxillary molars was significantly larger in the treated group than in the untreated

**Figure 1.** Superimposition of the cephalometric tracings showing the treatment changes of 40 Class II, Division 1 patients (20 women and 20 men) treated with the acrylic-splint Herbst appliance. The tracing of pretreatment is shown by a solid line. The tracing of post-Herbst is shown by a dotted line. Superimposition at the anterior cranial base (A). Class II molars were overcorrected with a posterior openbite. The maxilla moved downward while the mandible moved forward and downward as a consequence of an increase in mandibular length. There was a slight clockwise rotation of the palatal plane. The mandibular plane closed approximately 0.6°, which was not significantly different from that seen in the control. Maxillary regional superimposition showing the movements of the maxillary teeth within the maxilla (B). The molars were moved distally and held in position vertically while the incisors were not affected by the treatment. Mandibular regional superimposition showing the movements of the mandibular teeth within the mandible (C). The mandibular molars were moved forward and their eruptions were enhanced. The incisors were tipped forward and their eruptions were inhibited.

**Table 2.** Changes of Maxillary Molar Position During Herbst Therapy

Authors	Sample Size	Age (y)	Interval (mo)	Changes		P Value
				Herbst	Control	
Sagittal Changes						
Pancherz <sup>26</sup> 1982	22	12.1	6	-2.6	+0.2	<.01
McNamara et al <sup>34</sup> 1990	45	12.0	12	-1.4	+1.3	<.001
Pancherz et al <sup>35</sup> 1993	45	12.4	7	-2.1	+0.3	<.001
Windmiller <sup>31</sup> 1993	22	11.1	11.6	-0.7	+1.4	<.001
Franchi et al <sup>33</sup> 1999	55	12.8	12	-1.4	+0.4	Significant
Vertical Changes						
Valant et al <sup>30</sup> 1989	32	10.2	10	+0.2	+1.0	<.001
Pancherz et al <sup>35</sup> 1993	45	12.4	7	-0.7	+0.4	<.001
Lai et al <sup>32</sup> 1998	40	13.0	12	-0.2	+1.0	<.001

NOTE. +, Indicates mesial or extrusive movement; -, indicates distal or intrusive movement.

Class II patients. These posttreatment relapses counteracted the treatment effect of the Herbst appliance, thus, overall, the maxillary molars were not affected by the appliance in the sagittal direction.<sup>33</sup> Normal growth developmental changes prevail thereafter with respect to the maxillary dental changes (ie, the maxillary molars move mesially until growth is completed).<sup>35</sup> Vertical alveolar change, however, was comparable with that seen in the control group during a 17-month post-Herbst interval.<sup>32</sup> A shorter maxillary posterior alveolar height was noted at the end of 2-stage treatment.

#### The Influence of Retention on Posttreatment Relapse

It might be expected that the distal movement of the maxillary molars during Herbst therapy could be maintained if retention is achieved. In a short-term follow-up, there is a difference between the retention and unretained groups with respect to sagittal molar relapse after removal of the retainer. According to Pancherz and Hansen,<sup>27</sup> there is less relapse (1.1 mm,  $P < .01$ ) in the group retained with activator or maxillary plate than in the unretained group during the 12-month posttreatment period. The difference,

however, diminishes with time. Pancherz and Anehus-Pancherz<sup>35,36</sup> found that 1- to 2-year post-treatment retention on a long-term basis did not have a significant effect on the position of the maxillary molars.

### Effects on the Mandibular Dentition

#### Changes During Therapy

In addition to the maxillary molar distalization, mesial movement of the mandibular molars also contributes significantly to Class II molar correction during Herbst therapy.<sup>22,23,25-33</sup> In studies on the banded Herbst appliances, these changes usually are less than the distal movement of the maxillary molars (Table 1) and contribute approximately 20% to 30% of the overall correction.<sup>22,23,25-29</sup> In the acrylic Herbst studies, these changes are comparable and account for approximately 25% of the molar correction.<sup>31-33</sup>

Herbst appliances displace the mandibular dentition anteriorly to a greater extent when the resulting dentoalveolar changes are compared with those of the control group<sup>26,31,33,34,37</sup> or with data derived from a growth study.<sup>32</sup> The amount of dentoalveolar effects on mandibular molars was reported to be an average of 0.8 mm<sup>33</sup> to 2.2

**Table 3.** Skeletal and Dental Components of Class II Molar Correction as Class I Molar is Established

Authors	Molar Correction	Skeletal Change		Dental Change	
		Maxilla	Mandible	Maxilla	Mandible
Pancherz et al <sup>27</sup> 1986	+4.6*	-1.7	+4.2	+0.5	+1.6
Lai et al <sup>32</sup> 1998	+3.8†	-1.7	+4.7	-0.2	+1.0
Franchi et al <sup>33</sup> 1999	+3.7‡	-1.1	+4.2	-0.2	+0.9

NOTE. +, Indicates favorable change for correction; -, indicates unfavorable change for correction.

\*12 months post-Herbst treatment.

†17 months post-Herbst treatment.

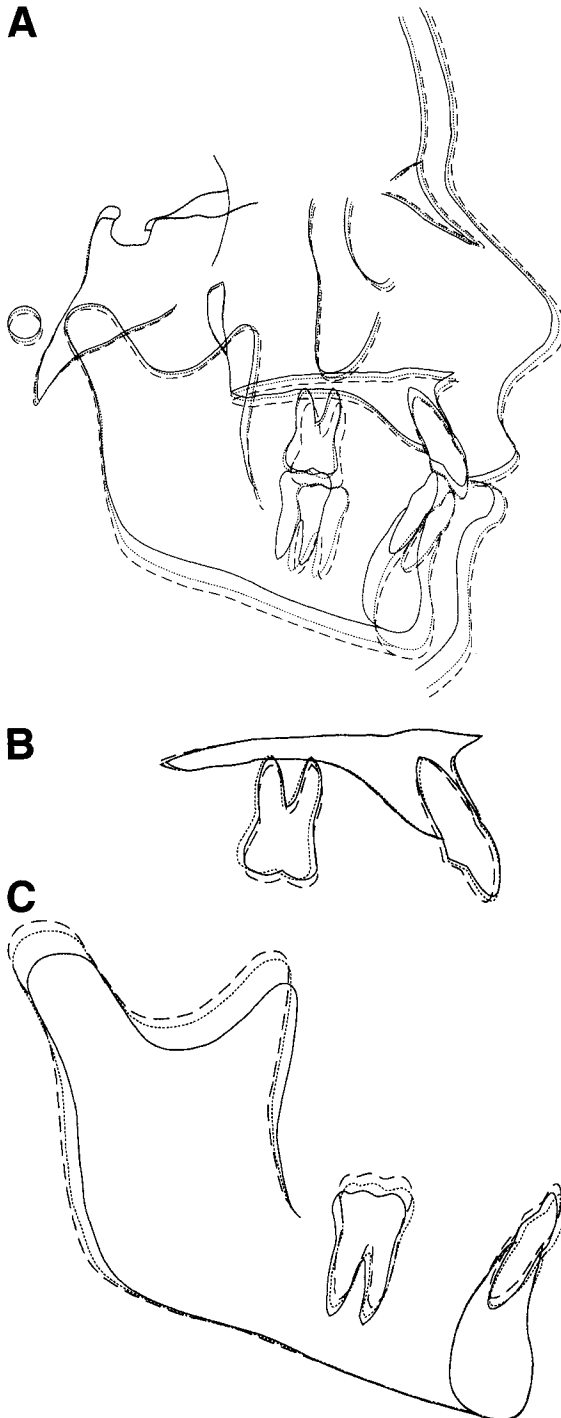
‡16 months post-Herbst treatment.

mm<sup>31</sup> (Table 4). A greater effect on the incisor position (Table 5), ranging from 1.7 mm<sup>33</sup> to 2.4 mm,<sup>37</sup> was reported with the exception of the study by Windmiller<sup>31</sup> in which no significant difference was noted between treated and control groups. In addition, proclination of mandibu-

lar incisors occurred concomitantly with the anterior displacement of the dentition.<sup>6,12,24,30,32,37-39</sup> The incisors were tipped forward to a significant level, with reported amounts ranging from an average of 2.0°<sup>30</sup> to 8.4°<sup>37</sup> (Table 6).

#### The Influence of Anchorage on Dental Movement

It seems clear that anterior displacement of the mandibular dentition has been a significant side effect of Herbst therapy. The lower anchorage could be increased by incorporating additional dental units into the appliance or splinting teeth together, thus, providing more of a skeletal correction and restricting anterior movement of the lower dentition. However, it has not yet been shown that any of the present anchorage systems used in Herbst treatment are able to prevent anterior movement of the mandibular teeth and proclination of incisors. The study by Pancherz and Hansen<sup>40</sup> comparing the effects of five different mandibular anchorage systems showed that anchorage loss was inevitable regardless of the anchorage system used. Even when using a



**Figure 2.** Superimposition of the cephalometric tracings showing the treatment changes of 40 Class II, Division 1 patients (20 women and 20 men) treated with the acrylic Herbst appliance immediately followed by a second phase of edgewise therapy. The tracing of pretreatment is shown by the solid line. The tracing of post-Herbst treatment is shown by the dotted line. The tracing of post-edgewise treatment is shown by the hyphenated line. Superimposition at the anterior cranial base (A). The maxilla moved downward and the mandible moved downward and slightly forward during the fixed appliance therapy. At the end of two-stage treatment, a Class I molar relationship was established. The palatal plane rotated back to pretreatment angulation. The mandibular plane closed approximately 0.8°, which was comparable with that seen in the control. Maxillary regional superimposition showing the movements of the maxillary teeth within the maxilla (B). During the edgewise treatment, the molars returned to their pretreatment positions sagittally and had a similar amount of eruption as that of the control, resulting in shorter maxillary posterior alveolar height when compared with the control. The incisors were retracted. Mandibular regional superimposition showing the movements of the mandibular teeth within the mandible (C). There was a partial relapse of dental movement for both molars and incisors. The mandibular dentition, however, were still positioned more anteriorly at the end of treatment.

**Table 4.** Changes of Mandibular Molar Position During Herbst Therapy

Authors	Sample Size	Age (y)	Interval (mo)	Changes		P Value
				Herbst	Control	
Pancherz <sup>26</sup> 1982	22	12.1	6	+1.3	+0.3	<.001
Pancherz et al <sup>37</sup> 1985	29	12.0	7	+1.7	+0.2	<.001
McNamara et al <sup>34</sup> 1990	45	12.0	12	+1.4	+0.5	<.001
Windmiller <sup>31</sup> 1993	22	11.1	11.6	+1.7	-0.5	<.001
Lai et al <sup>32</sup> 1998	40	13.0	12	+1.5	+0.1	<.001
Franchi et al <sup>33</sup> 1999	55	12.8	12	+1.4	+0.6	Significant

NOTE. + Indicates mesial tooth movement. - indicates distal tooth movement.

chrome cast framework for anchorage<sup>12</sup> or splinting teeth together as one rigid unit,<sup>30-33</sup> dentoalveolar changes in the mandibular arch could not be avoided, although there are less mandibular dentoalveolar changes reported in the studies using acrylic Herbst appliances.<sup>30-33</sup>

#### The Influence of Somatic Maturation on Dental Movement

When the amount of mandibular tooth movement was related to the maturation level of the treated patient, it did not seem that the growth period in which the patient was treated was an important concern provided that treatment did not start very late during growth.<sup>37,41,42</sup> In patients whose Herbst therapies started 1-year postpubertal growth, greater changes in the positions of the mandibular incisors were reported.<sup>29,37,41</sup>

#### The Influence of Incisor Proclination on Gingiva

The effect of orthodontic proclination of the mandibular incisors on gingival recession has been a subject of debate. Ruf et al<sup>43</sup> investigated the relationship between the amount of mandibular incisor proclination during treatment and the development of gingival recession 6 months after treatment in 98 children and adolescents. A

total of 392 mandibular incisors were examined. Only 12 of the 392 teeth developed a recession or their preexisting recessions became worse. No relationship was found between the amount of proclination and the increase in crown length or development of recession. Therefore, they concluded that labial movement of mandibular incisors did not result in gingival recession.

#### Posttreatment Changes

Dental relapses after the removal of the Herbst appliance also are evident in the mandibular dentition. In contrast to the maxillary molars, mandibular molars do not tend to return to their pretreatment position. Class II molar corrections occur as a result of mandibular skeletal changes and mesial movement of the mandibular molars at the end of the 12-month post-treatment period<sup>27</sup> or the end of 2-stage treatment<sup>32,33</sup> (Table 3).

On a short-term basis, although rebound occurs after the appliance is removed, the effects of the Herbst appliance on the mandibular dentition seem to be maintained, but to a lesser extent (ie, more anteriorly positioned mandibular teeth and more proclined mandibular incisors when compared with the controls).<sup>32,33</sup> These effects on the mandibular dentition are maintained throughout the growth period.<sup>44</sup>

**Table 5.** Changes of Mandibular Incisor Position During Herbst Therapy

Authors	Sample Size	Age (y)	Interval (mo)	Changes		P Value
				Herbst	Control	
Pancherz <sup>26</sup> 1982	22	12.1	6	+1.8	+0.0	<.001
Pancherz et al <sup>37</sup> 1985	29	12.0	7	+2.4	+0.0	<.001
McNamara et al <sup>34</sup> 1990	45	12.0	12	+1.6	-0.4	<.001
Windmiller <sup>31</sup> 1993	21	11.1	11.6	+1.1	+0.4	NS
Lai et al <sup>32</sup> 1998	40	13.0	12	+1.6	-0.5	<.001
Franchi et al <sup>33</sup> 1999	55	12.8	12	+1.3	-0.4	S

NOTE. +, Indicates mesial tooth movement; -, indicates distal tooth movement. Abbreviations: NS, not significant; S, significant.

**Table 6.** Changes of Mandibular Incisor Inclination During Herbst Therapy

Authors	Sample Size	Age (y)	Interval (mo)	Changes		P Value
				Herbst	Control	
Pancherz <sup>6</sup> 1979	10	Prepubertal	6	+5.4	0.0	<.001
Wieslander <sup>12</sup> 1984	18	8.3	5	+3.6	+0.3	<.01
Pancherz et al <sup>37</sup> 1985	29	12.0	7	+8.3	-0.1	<.001
Valant et al <sup>30</sup> 1989	32	10.2	10	+2.5	+0.5	<.05
Sidhu et al <sup>24</sup> 1995	8	11.8	8	+4.9	-0.4	<.05
Lai et al <sup>32</sup> 1998	40	13.0	12	+5.1	-0.5	<.001

NOTE. +, Indicates labial proclination; - indicates lingual retroclination.

### Stability

Long-term stability of the mandibular dentition, the incisors in particular, has been of primary concern because there is a strong tendency for the teeth to return to their pretreatment position. Many orthodontists believe that this tendency eventually will overtake the treatment effect and that relapse will occur in the buccal segments or result in the development of post-treatment crowding.

In a long-term study on the results of Herbst treatment, Pancherz<sup>36</sup> compared two groups of Herbst-treated patients with and without relapse in the occlusion. Skeletal and dentoalveolar changes in the mandibular arch were found to be similar in both groups 5 years after treatment. The reason for relapse was thought to be the anterior movements of maxillary dentition owing to muscular influence from the lips or tongue, or to an unstable occlusal condition after treatment.

The mandibular incisors are displaced anteriorly to a great extent during treatment and recover partially during the immediate posttreatment period. This overall movement results in a net effect of slightly more anteriorly positioned teeth. In the short-term follow-up, the movements of the incisors do not seem to cause crowding of the lower anteriors.<sup>45,46</sup> In a long-term perspective, Hansen et al<sup>46</sup> assessed the relationship between the changes of mandibular incisor inclination and the development of anterior crowding. They found that the decrease of available space and increase in irregularity index were similar between the Herbst-treated patients and the untreated normal subjects during a 5- to 10-year follow-up period. Thus, the development of incisal crowding was thought to be associated with normal craniofacial growth changes rather than the use of the Herbst appliance.

### Discussion

Distalization of maxillary molars into a Class I relationship is one treatment modality for Class II malocclusions. This movement can be achieved by either extraoral traction<sup>48-50</sup> or intraoral appliances such as removable plates,<sup>51</sup> repelling magnets,<sup>52-57</sup> nickel-titanium coil springs,<sup>56-59</sup> superelastic wires,<sup>60</sup> the Pendulum appliance (Ormco Corp, Orange, CA),<sup>61-64</sup> the Wilson arch (Rocky Mountain Orthodontics, Denver, CO),<sup>65</sup> Herbst appliances,<sup>22-35</sup> the Jasper Jumper (American Orthodontics, Sheboygan, WI),<sup>18</sup> and sliding jigs with Class II elastics.<sup>66</sup>

Molar distalization usually can be achieved in a relatively short period of time (3 to 4 months) with repelling magnets,<sup>54-57</sup> superelastic coil springs,<sup>56-58</sup> the Pendulum appliance,<sup>61-64</sup> or the Wilson arch.<sup>65</sup> These appliances produced distal movement at the rate of 0.6 to 1.2 mm per month. In comparison, the Herbst appliance displaced the maxillary molars at a slower rate (Table 1). This reduced rate of movement could be due in part to the fact that the Herbst appliance was originally designed to alter the growth of basal bones rather than to distalize the maxillary molars. Premolars and/or anterior teeth, in addition to molars, are incorporated into the appliance to restrict undesirable dentoalveolar movements.

In the correction of Class II malocclusions, moving the maxillary molars distally without intrusion usually is undesirable, especially in those patients with hyperdivergent growth patterns, because of the tendency to rotate the mandible downward and backward. The Herbst telescoping bite-jumping mechanism places a distal and intrusive force on the maxillary molars and the force vector passes occlusally to the center of resistance. This force system produces

backward and upward movements of maxillary molars in conjunction with distal crown tipping.<sup>67</sup> Because of the intrusive effect, distal movements of maxillary molars do not tend to open the mandible.<sup>6,12,30-32,34</sup> These effects are similar to those produced by high-pull headgear.<sup>48-50</sup> In contrast, most of the rapid molar distalization appliances tend to cause the mandible to rotate downward and backward, opening the mandibular plane angle. Of the seven studies<sup>55,56,58,61-64</sup> that evaluated the mandibular plane changes during distalization, five studies<sup>56,58,61,62,64</sup> reported that the mandible rotated downward and backward approximately 1°.

The Herbst appliance, like other interarch Class II mechanics such as Class II elastics and the Wilson arch, uses the mandibular arch as anchorage to distalize the maxillary molars. The reciprocal force displaces the mandibular dentition anteriorly and proclines the incisors.<sup>65,66</sup> Although all of these appliances are effective in correcting the sagittal relationship of the dentition, the vertical changes produced by these appliances differ. The vertical force of Class II elastics extrudes the maxillary incisors and mandibular molars, and these changes result in a clockwise rotation of the occlusal and the mandibular planes as well as an increase in lower anterior facial height.<sup>66</sup> The intrusive force of the Herbst appliance on the maxillary molars and mandibular anterior teeth results in an increase in the occlusal plane angle, whereas it has no treatment effect on the mandibular plane.<sup>6,12,30-32,34</sup>

## Summary

The Herbst appliance exhibits a pronounced high-pull headgear effect on the maxillary molars. Without retention, the molars tend to return to their former anteroposterior positions after the removal of the appliance. These distal movements of the maxillary molars are favorable in Class II correction. Reciprocal mesial movements of the mandibular dentition, on the other hand, may not be desirable in many instances. Even though partial recovery occurs after Herbst therapy, treatment effects can persist in the mandibular arch. The latter effect can be beneficial to those patients who have initial retroclined mandibular incisors, but unfavorable in those

patients with proclined lower incisors at the beginning of treatment.

## Acknowledgment

The author thanks Dr George Cisneros, James A. McNamara, Jr, and Leslie A. Will for their assistance in the preparation of this manuscript.

## References

1. Herbst E. Atlas und Grundriss der Zahnärztlichen Orthopädie. Munich, Germany, J.F. Lehmann Verlag, 1910.
2. Herbst E. Dreissigjährige Erfahrungen mit dem Retentions-Scharnier. Zahnärztl Rundschau 1934;43:1515-1524, 1563-1568, 1611-1616.
3. White LW. Current Herbst appliance therapy. J Clin Orthod 1994;28:296-309.
4. Smith JR. Matching the Herbst to the malocclusion. Three types of stainless steel crown Herbsts. Clin Impres 1998;7:6-12, 20-23.
5. Hilgers JJ. Hyperefficient orthodontic treatment using tandem mechanics. Semin Orthod 1998;4:17-25.
6. Pancherz H. Treatment of Class II malocclusions by jumping the bite with the Herbst appliance. A cephalometric investigation. Am J Orthod 1979;76:423-442.
7. Langford NM Jr. The Herbst appliance. J Clin Orthod 1981;15:558-561.
8. Langford NM Jr. Updating fabrication of the Herbst appliance. J Clin Orthod 1982;16:173-174.
9. Goodman P, McKenna P. Modified Herbst appliance for the mixed dentition. J Clin Orthod 1985;19:811-814.
10. Dischinger TG. Edgewise bioprogressive Herbst appliance. J Clin Orthod 1989;23:608-617.
11. Dischinger TG. Edgewise Herbst appliance. J Clin Orthod 1995;29:738-742.
12. Wieslander L. Intensive treatment of severe Class II malocclusions with a headgear-Herbst appliance in the early mixed dentition. Am J Orthod 1984;86:1-13.
13. Howe RP. The bonded Herbst appliance. J Clin Orthod 1982;16:663-667.
14. Howe RP. Updating the bonded Herbst appliance. J Clin Orthod 1983;17:122-124.
15. McNamara JA Jr. Fabrication of the acrylic splint Herbst appliance. Am J Orthod Dentofacial Orthop 1988;94:10-18.
16. McNamara JA Jr, Howe RP. Clinical management of the acrylic splint Herbst appliance. Am J Orthod Dentofacial Orthop 1988;94:142-149.
17. Zreik T. A fixed-removable Herbst appliance. J Clin Orthod 1994;28:246-248.
18. Jasper JJ, McNamara JA Jr. The correction of interarch malocclusions using a fixed force module. Am J Orthod Dentofacial Orthop 1995;108:641-650.
19. Miller RA. The flip-lock Herbst appliance. J Clin Orthod 1996;30:552-558.
20. Schiavoni R, Bonapace C, Grenga V. Modified edgewise-Herbst appliance. J Clin Orthod 1996;30:681-687.
21. Haeggund P, Segerdal S. The Swedish-style integrated Herbst appliance. J Clin Orthod 1997;31:378-390.



22. Ruf S, Pancherz H. The mechanism of Class II correction during Herbst therapy in relation to the vertical jaw base relationship: A cephalometric roentgenographic study. *Angle Orthod* 1997;67:271-276.
23. Obijou C, Pancherz H. Herbst appliance treatment of Class II, division 2 malocclusions. *Am J Orthod Dentofacial Orthop* 1997;112:287-291.
24. Sidhu MS, Kharbanda OP, Sidhu SS. Cephalometric analysis of changes produced by a modified Herbst appliance in the treatment of Class II division 1 malocclusion. *Br J Orthod* 1995;22:1-12.
25. Wong GWK, So LLY, Hägg U. A comparative study of sagittal correction with the Herbst appliance in two different ethnic groups. *Eur J Orthod* 1997;19:195-204.
26. Pancherz H. The mechanism of Class II correction in Herbst appliance treatment. A cephalometric investigation. *Am J Orthod* 1982;82:104-113.
27. Pancherz H, Hansen K. Occlusal changes during and after Herbst treatment: A cephalometric investigation. *Eur J Orthod* 1986;8:215-228.
28. Pancherz H, Malmgren O, Hägg U, et al. Class II correction in Herbst and Bass therapy. *Eur J Orthod* 1989;11:17-30.
29. Konik M, Pancherz H, Hansen K. The mechanism of Class II correction in late Herbst treatment. *Am J Orthod Dentofacial Orthop* 1997;112:87-91.
30. Valant JR, Sinclair PM. Treatment effects of the Herbst appliance. *Am J Orthod Dentofacial Orthop* 1989;95:138-147.
31. Windmiller EC. The acrylic-splint Herbst appliance: A cephalometric evaluation. *Am J Orthod Dentofacial Orthop* 1993;104:73-84.
32. Lai M, McNamara JA Jr. An evaluation of two-phase treatment with the Herbst appliance and preadjusted edgewise therapy. *Semin Orthod* 1998;4:46-58.
33. Franchi L, Baccetti T, McNamara JA Jr. Treatment and posttreatment effects of acrylic splint Herbst appliance therapy. *Am J Orthod Dentofacial Orthop* 1999;115:429-438.
34. McNamara JA Jr, Howe RP, Dischinger TG. A comparison of the Herbst and Fränkel appliances in the treatment of Class II malocclusion. *Am J Orthod Dentofacial Orthop* 1990;98:134-144.
35. Pancherz H, Anehus-Pancherz M. The headgear effect of the Herbst appliance: A cephalometric long-term study. *Am J Orthod Dentofacial Orthop* 1993;103:510-520.
36. Pancherz H. The nature of Class II relapse after Herbst appliance treatment. A cephalometric long-term investigation. *Am J Orthod Dentofacial Orthop* 1991;100:220-233.
37. Pancherz H, Hägg U. Dentofacial orthopedics in relation to somatic maturation. An analysis of 70 consecutive cases treated with the Herbst appliance. *Am J Orthod* 1985;88:273-287.
38. Pancherz H. The effect of continuous bite jumping on the dentofacial complex. A follow-up study after Herbst appliance treatment of Class II malocclusions. *Eur J Orthod* 1981;3:49-60.
39. Pancherz H. The Herbst appliance—Its biologic effects and clinical use. *Am J Orthod* 1985;87:1-20.
40. Pancherz H, Hansen K. Mandibular anchorage in Herbst treatment. *Eur J Orthod* 1988;10:149-164.
41. Hägg U, Pancherz H. Dentofacial orthopaedics in relation to chronological age, growth period and skeletal development. An analysis of 72 male patients with Class II division 1 malocclusion treated with the Herbst appliance. *Eur J Orthod* 1988;10:169-176.
42. Hansen K, Pancherz H, Hägg U. Long-term effects of the Herbst appliance in relation to the treatment growth period: A cephalometric study. *Eur J Orthod* 1991;13:471-481.
43. Ruf S, Hansen K, Pancherz H. Does orthodontic proclination of lower incisors in children and adolescents cause gingival recession? *Am J Orthod Dentofacial Orthop* 1998;114:100-106.
44. Hansen K, Pancherz H. Long-term effects of Herbst treatment in relation to normal growth development: A cephalometric study. *Eur J Orthod* 1992;14:285-295.
45. Hansen K, Iemamnuiesuk P, Pancherz H. Long-term effects of the Herbst appliance on the dental arches and arch relationships: A biometric Study. *Br J Orthod* 1995;22:123-134.
46. Hansen K, Koutsonas TG, Pancherz H. Long-term effects of Herbst treatment on the mandibular incisor segment: A cephalometric and biometric investigation. *Am J Orthod Dentofacial Orthop* 1997;112:92-103.
47. Wieslander L. Long-term effect of treatment with the headgear-Herbst appliance in the early mixed dentition. Stability or relapse? *Am J Orthod Dentofacial Orthop* 1993;104:319-329.
48. Brown P. A cephalometric evaluation of high-pull molar headgear and face-bow neck strap therapy. *Am J Orthod* 1978;74:621-632.
49. Baumrind S, Korn EL, Isaacson RJ, et al. Quantitative analysis of the orthodontic and orthopedic effects of maxillary traction. *Am J Orthod* 1983;84:384-398.
50. Firouz M, Zernik J, Nanda R. Dental and orthopedic effects of high-pull headgear in treatment of Class II, Division 1 malocclusion. *Am J Orthod Dentofacial Orthop* 1992;102:197-205.
51. Cetlin NM, Ten Hoeve A. Nonextraction treatment. *J Clin Orthod* 1983;17:396-413.
52. Gianelly AA, Vaitas AS, Thomas WM, et al. Distalization of molars with repelling magnets. *J Clin Orthod* 1988;22:40-44.
53. Gianelly AA, Vaitas AS, Thomas WM. The use of magnets to move molars distally. *Am J Orthod Dentofacial Orthop* 1989;96:161-167.
54. Itoh T, Tokuda T, Kiyosue S, et al. Molar distalization with repelling magnets. *J Clin Orthod* 1991;25:611-617.
55. Bondemark L, Kurol J. Distalization of maxillary first and second molars simultaneously with repelling magnets. *Eur J Orthod* 1992;14:264-272.
56. Bondemark L, Kurol J, Bernhold M. Repelling magnets versus superelastic nickel-titanium coils in simultaneous distal movement of maxillary first and second molars. *Angle Orthod* 1994;64:189-198.
57. Erverdi N, Koyutürk Ö, Küçükkeles N. Nickel-titanium coil springs and repelling magnets: A comparison of two different intra-oral molar distalization techniques. *Br J Orthod* 1997;24:47-53.
58. Gulati S, Kharbanda OP, Parkash H. Dental and skeletal changes after intraoral molar distalization with sectional

- jig assembly. *Am J Orthod Dentofacial Orthop* 1998;114:319-327.
59. Gianelly AA, Bednar J, Dietz VS. Japanese NiTi coils used to move molars distally. *Am J Orthod Dentofacial Orthop* 1991;99:564-566.
  60. Locatelli R, Bednar J, Dietz VS, et al. Molar distalization with superelastic NiTi wire. *J Clin Orthod* 1992;26:277-279.
  61. Ghosh J, Nanda RS. Evaluation of an intraoral maxillary molar distalization technique. *Am J Orthod Dentofacial Orthop* 1996;110:639-646.
  62. Bussick TJ. A cephalometric evaluation of skeletal and dentoalveolar changes associated with maxillary molar distalization with the pendulum appliance. Master's Thesis, University of Michigan, Ann Arbor, MI, 1997.
  63. Byloff FK, Darendeliler MA. Distal molar movement using the pendulum appliance. Part I: Clinical and radiological evaluation. *Angle Orthod* 1997;67:249-260.
  64. Byloff FK, Darendeliler MA, Clar E, et al. Distal molar movement using the pendulum appliance. Part II: The effects of maxillary molar root uprighting bends. *Angle Orthod* 1997;67:261-270.
  65. Muse DS, Fillman MJ, Emmerson WJ, et al. Molar and incisor changes with Wilson rapid molar distalization. *Am J Orthod Dentofacial Orthop* 1993;104:556-565.
  66. Proffit WR, Fields HW Jr. *Contemporary orthodontics* (3rd ed). St Louis, MO, Mosby-Year Book, 1998, pp 552-577.
  67. Greenspan RA. Reference charts for controlled extraoral force application to maxillary molars. *Am J Orthod* 1970;58:486-491.